

Case report

Successful resolution of mesenteric tuberculosis and HIV co-infection following 6 months of anti-tuberculosis therapy: a case report

Novita Maulidiyah¹, Ramadi S Wicaksono^{2*}, Aisyah R Retnowulan¹, Budi Santoso², Aries Subianto¹, Latifah Mashudi³, Fajar Kurniawan⁴

¹Department of Pulmonology & Respiratory Medicine, RSUD Bangil Kabupaten Pasuruan, Pasuruan, Indonesia; ²Department of Internal Medicine, RSUD Bangil Kabupaten Pasuruan, Pasuruan, Indonesia; ³Department of Public Health, RSUD Bangil Kabupaten Pasuruan, Pasuruan, Indonesia; ⁴Department Anesthesiology, RSUD Bangil Kabupaten Pasuruan, Pasuruan, Indonesia.

*Corresponding author: Ramadi Satryo Wicaksono (Email: ramadi_satryo@yahoo.com)

Citation: Maulidiyah N, Wicaksono RS, Retnowulan AR, Santoso B, Subianto A, Mashudi L, Kurniawan F. Successful resolution of mesenteric tuberculosis and HIV co-infection following 6 months of anti-tuberculosis therapy: a case report. *Deka in Medicine*. 2024; 1(1): e738

Received: March 12, 2024
Revised: March 20, 2024
Accepted: March 21, 2024
Published: March 30, 2024



Copyright: © 2024 by the authors. This is an open access article distributed under the terms and conditions of the CC BY-SA 4.0

ABSTRACT

BACKGROUND: Mesenteric tuberculosis (TB), a rare extrapulmonary variant of TB, poses diagnostic and therapeutic challenges in its management. Therefore, discussing a case of mesenteric TB is both intriguing and informative for gaining insights into its clinical presentation and optimal treatment strategies.

CASE PRESENTATION: A 50-year-old male presented symptoms of blackish stools three days post-gallstone surgery, accompanied by approximately two months of abdominal discomfort, described as squeezing or stabbing, alleviated temporarily by analgesics, alongside abdominal distension, rigidity, decreased appetite, and afternoon fevers. Physical examination revealed normal vital signs, with pale conjunctiva and asymmetrical chest wall movement, dull percussion, and decreased breath sounds in the lower left hemithorax. Abdominal inspection indicated distension, postsurgical signs, and ascites. Following laboratory investigations, chest and abdominal radiographs, and tissue biopsies, the patient was diagnosed with HIV co-infection along with pulmonary and mesenteric TB. Treatment comprised an intensive phase of four fixed-dose combinations (FDC) of anti-TB drugs, followed by a continuation phase of two FDC tablets, alongside first-line antiretroviral (ARV) therapy and cotrimoxazole prophylaxis. By the sixth month follow-up, clinical improvement was observed, with resolution of symptoms and weight gain to 56 kg.

CONCLUSION: This case highlights the effective management of mesenteric TB and HIV co-infection, emphasizing the importance of comprehensive care and collaborative efforts between TB and HIV/AIDS control programs.

KEYWORDS: Mesenteric tuberculosis; Human Immunodeficiency Virus; diagnosis; management.

INTRODUCTION

Tuberculosis (TB) remains a significant global public health challenge, despite Indonesia's successful achievement of targets set by the Millennium Development Goals (MDGs) in its TB control program. However, the concurrent rise in Human Immunodeficiency Virus (HIV) infections poses a double burden and is expected to contribute to an increase in TB cases within the community. Hence, collaboration between TB control programs and HIV/AIDS control efforts is imperative.¹ The HIV

epidemic has had a profound impact on the escalation of the TB epidemic worldwide, leading to a surge in TB cases. Managing the HIV pandemic presents a significant challenge for TB control. In Indonesia, approximately one-third of TB patients are HIV positive, while TB remains the most common opportunistic infection in nearly half of people living with HIV/AIDS (PLWHA).² TB detection in HIV patients, especially when extrapulmonary, presents particular complexities. Extrapulmonary TB cases in HIV patients include lymph nodes (50%) in various regions, such as the jugular, submandibular, and supraclavicular areas, among others. Other extrapulmonary organ TB cases are also noted, such as in the nasopharynx, skin and soft tissue, bones and joints, breast, uterus and adnexa, testes, kidney and bladder, thyroid, and abdominal regions. Among these extrapulmonary TB cases, mesenteric TB is rarely reported and poses challenges in both diagnosis and management.^{3,4}

Mesenteric TB represents a rare variant of extrapulmonary TB, predominantly affecting the peritoneal cavity, mesentery, and omentum, with manifestations encompassing fever, weight loss, abdominal pain, and distension.⁵ Despite its rarity, mesenteric TB remains a significant health concern, notably in developing nations and among populations with heightened TB susceptibility due to factors such as immunocompromised states, HIV infection, diabetes mellitus, peritoneal dialysis, or migration from regions with high TB prevalence.⁶ Managing mesenteric TB may pose challenges due to its paucibacillary nature, diagnostic ambiguity, variability in clinical approaches, and limited evidence-based guidelines.⁷ Given the complexity of its management and the infrequency of cases, presenting a case report becomes particularly compelling. In this context, we present a case of mesenteric TB in an HIV-positive individual, aiming to provide insights that may aid in accurate diagnosis and appropriate treatment strategies.

CASE PRESENTATION

A 50-year-old male presented at the emergency department of Bangil Hospital with a chief complaint of melena. He reported experiencing dark stools persisting for three days following cholecystectomy, accompanied by progressive abdominal distension and firmness. The patient had been experiencing abdominal discomfort for approximately two months, characterized by intermittent squeezing or stabbing sensations that occurred nearly daily, sometimes impeding his routine activities. While analgesic medication provided temporary relief, the symptoms recurred, and the patient noted increasing abdominal rigidity. Furthermore, since the onset of symptoms, he reported diminished appetite and afternoon fevers. Notably, the patient denied any respiratory symptoms. In terms of social history, he is married, works as an entrepreneur, and smokes two packs of cigarettes daily. He has a history of unprotected sexual intercourse and alcohol consumption but no history of tattoos.

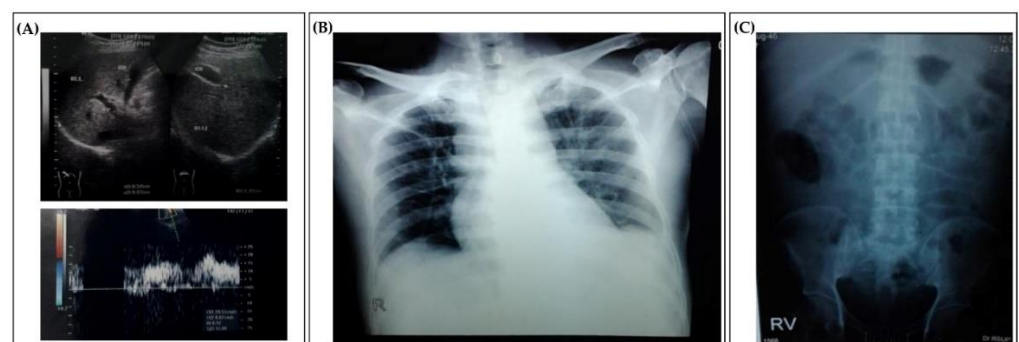

Figure 1. Radiological findings of our patients. (A). The abdominal ultrasound confirmed the presence of cholecystitis and cholelithiasis in the neck of the gallbladder. (B). The chest X-ray

showed minimal pleural effusion. (C). Plain abdominal radiograph revealed ascites with mild distension of the small intestine in the lower left abdomen.

During the physical examination, the patient exhibited moderate pain and was conscious. Vital signs were within normal ranges, including a blood pressure of 110/80 mmHg, a pulse rate of 86 beats per minute, a respiratory rate of 20 breaths per minute, and a temperature of 36.4°C. Ocular examination revealed pale conjunctiva and non-icteric sclera. No palpable lymphadenopathy was detected in the neck, axilla, or inguinal regions. Thoracic assessment indicated a normal-sized heart without evidence of vessel dilation or cutaneous edema. However, there was asymmetrical movement of the left chest wall, along with dullness noted in the lower left hemithorax at the sixth intercostal space and diminished vesicular breath sounds. Abdominal inspection revealed no distension or tenderness, although signs of surgery were evident, and ascites were present. Hepatomegaly and splenomegaly were absent. Both upper and lower extremities exhibited warmth without evidence of edema.

On September 12, 2021, abdominal ultrasonography conducted by a radiology specialist detected a gallbladder of normal dimensions, with walls thickened to 0.58 cm. Small calculi measuring 0.30 cm were identified in the neck of the gallbladder, showing no posterior acoustic shadowing or mass. The diagnosis of cholecystitis and cholelithiasis in the neck of the gallbladder was established based on these findings (Figure 1A). Subsequent ultrasonographic assessment on December 16, 2021, revealed the presence of ascites without evidence of peritoneal thickening or lymphadenopathy. Chest radiography performed on December 12, 2021, depicted a normal-sized heart and unremarkable lung fields, with dullness noted in the left phrenicocostal sinus and minimal left pleural effusion observed on an asymmetrical image (Figure 1B). Additionally, plain abdominal radiography on the same date confirmed the presence of ascites, accompanied by mild distension of the small intestine in the lower left abdomen (Figure 1C).

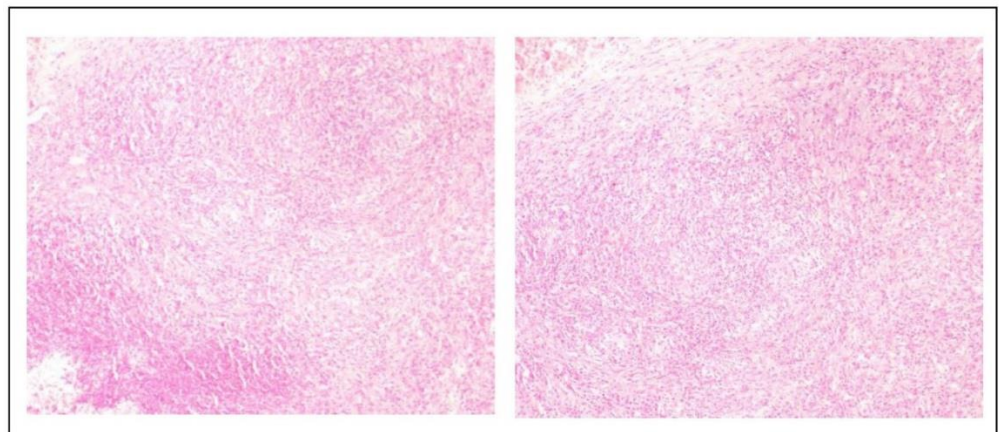


Figure 2. Microscopic analysis of the mesenteric tissue in anatomical pathology indicated the presence of chronic granulomatous lymphadenitis.

During surgical intervention, tissue analysis was undertaken to identify a specific infection or malignancy. Samples were obtained from both the gallbladder and mesentery. Histological examination of the gallbladder revealed non-specific chronic cholecystitis, while mesentery specimens exhibited fibrotic lymph node tissue with dense macrophage infiltration, displaying a granulomatous appearance without evidence of caseous necrosis (Figure 2). Polymorphonuclear (PMN) cells were also noted, with no presence of lymphocytes or malignant cells observed. The diagnosis

was indicative of metastatic carcinoma with chronic granulomatous lymphadenitis, suggestive of the initial phases of tuberculous lymphadenitis. Tissue examination results were reported on December 16, 2021, leading to the diagnosis of mesentery TB. Following confirmation of the diagnosis, the patient commenced an intensive phase of anti-TB therapy on December 16, 2021, consisting of four fixed-dose combinations (FDC) administered as three tablets, adjusted for a body weight of 50 kg. TB PCR analysis of ascitic fluid on December 17, 2021, yielded negative results. Discharge took place on December 20, 2021, for outpatient follow-up due to observed clinical improvement. Evaluation of treatment efficacy included clinical microbiological examinations of sputum samples conducted three times during the second month of treatment, with findings indicating negativity for TB on February 21, 2022.

During the advanced phase of TB treatment on February 14, 2022, the patient presented with complaints of dyspnea, cough with expectoration, and fever. Subsequently, on February 24, 2022, the patient was admitted to the hospital for a three-day period due to these symptoms, although the specific diagnosis was undisclosed. Examination results from February 21, 2022, indicated the detection of HIV-1 RNA at a level of 4.08×10^5 copies/mL, accompanied by reduced blood lymphocyte levels, particularly in T helper lymphocytes, with an absolute CD4 count of 95 cells/L. A chest X-ray conducted on February 24, 2022, upon hospital admission, revealed symmetrical positioning and cardiac abnormalities, along with bilateral pulmonary infiltrates (Figure 3A).

On March 4, 2022, the patient attended a follow-up appointment at the pulmonary polyclinic of Bangil Hospital, presenting with decreased dyspnea, reduced coughing, absence of fever, and newly reported skin pruritus. Despite these improvements, the patient declined admission. Subsequent consultation at the VCT polyclinic confirmed stage IV HIV infection, prompting initiation of antiretroviral (ARV) therapy comprising AZT/3TC/EFV and cotrimoxazole, alongside two FDCs of anti-TB medication. A chest X-ray performed on March 20, 2022, revealed reduced fibroinfiltrates in both hemithoraces compared to the image captured on February 24, 2022 (Figure 3B). By the sixth month of anti-TB therapy, the patient exhibited clinical amelioration, characterized by the absence of dyspnea, cough, fever, and abdominal pain, coupled with improved appetite and weight gain to 56 kg. Subsequent chest X-ray evaluation on June 2, 2022, depicted symmetrical findings with no cardiac anomalies, while evidence of lung fibrosis was noted in the right paracardial region (Figure 3C).

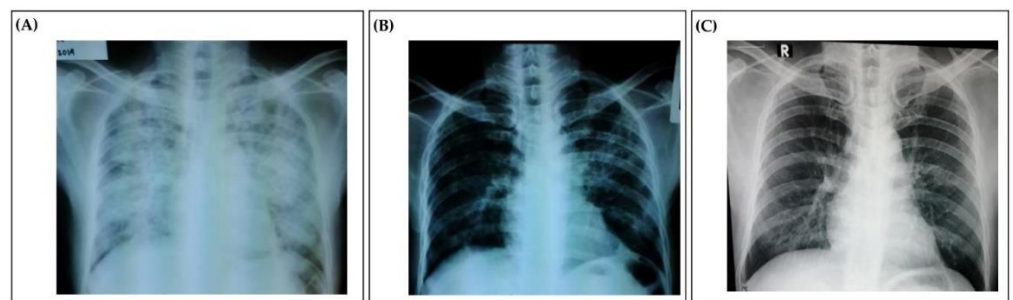


Figure 3. The patient's evolution was evaluated through radiological examinations. (A). Chest X-ray findings indicated PCP, pulmonary TB, and CAP. (B). Chest X-ray indicating pulmonary TB. (C). Chest X-ray revealing fibrosis adjacent to the right side of the heart.

DISCUSSION

The patient featured in our case study was diagnosed with HIV concurrent with mesenteric TB. Symptoms included intermittent abdominal pain, ascites,

hematochezia, melena, reduced appetite, and weight loss. Mesenteric TB diagnosis in our case study was confirmed by the presence of chronic granulomatous lymphadenitis, indicative of initial tuberculous lymphadenitis stages. Our diagnostic process aligned with established literature standards. Mesenteric TB diagnosis typically involves anatomic histopathology, ultrasound examination, *M. tuberculosis* culture, and smear analysis.⁸ Moreover, another study also revealed four criteria for diagnosing mesenteric TB, encompassing histological tubercle evidence with caseous necrosis, identification of TB in mesenteric lymph node biopsies, *M. tuberculosis* growth in tissue culture, and detection of acid-fast bacilli in histological samples.⁶ In our case, laparoscopic sampling was conducted, representing a valuable diagnostic tool for abdominal TB. Laparoscopy yields diagnostic accuracy up to 94%, necessitating histological confirmation. Laparoscopy with biopsy stands as the diagnostic gold standard for abdominal TB, boasting an 85%-95% diagnostic accuracy. However, technical challenges may arise due to adhesive tissue and limited abdominal space, occasionally requiring diagnostic laparotomy.⁹ According to the elucidation provided, it can be affirmed that our diagnostic approach for mesenteric TB conformed to established protocols.

The mechanism underlying mesenteric TB is intricate, and the factors contributing to its development in our patient remain an intriguing subject for exploration. In mesenteric TB, lymph node involvement occurs in approximately two-thirds of patients with abdominal TB, commonly affecting multiple lymph node groups concurrently. Predominantly, the mesenteric and peripancreatic clusters are implicated, reflecting the lymphatic drainage patterns of frequently affected sites such as the small intestine and liver.¹⁰ Primary TB lesions typically manifest in the small intestine and mesenteric lymph nodes. As TB progresses, lymph nodes undergo enlargement and softening, leading to leakage of TB-infected material into the abdominal cavity, resulting in the accumulation of ascitic fluid and abdominal distension.⁶ Alternatively, in certain instances, lymph nodes may adhere to the intestinal wall without rupture, causing discomfort and episodes of obstruction, potentially culminating in complete gastrointestinal obstruction.¹⁰

The management of mesenteric TB poses a multifaceted challenge and requires ongoing and comprehensive monitoring. In this instance, the intensive phase of anti-TB treatment consisted of four FDCs comprising Rifampicin, Isoniazid, Pyrazinamide, and Ethambutol, administered as three tablets each. Subsequently, the continuation phase involved two FDCs containing Rifampicin and Isoniazid, also administered as three tablets each. Additionally, first-line ARV therapy comprised two nucleoside reverse transcriptase inhibitors (NRTIs) along with Efavirenz (EFV). The management of mesenteric TB coinfecting with HIV in our study adhered to standard guidelines. Recommended treatment for TB-HIV coinfection includes an initial two-month phase involving Isoniazid, Rifampicin, Pyrazinamide, and Ethambutol, followed by four months of Isoniazid and Rifampicin or six months of Isoniazid and Ethambutol.¹¹ However, administering Isoniazid and Ethambutol for six months during the continuation phase is not advisable for TB patients with HIV due to the increased risk of treatment failure or relapse.¹² ARV therapy initiation is recommended within 2-8 weeks of the initial TB treatment phase. Efavirenz is preferred among non-nucleoside reverse transcriptase inhibitors (NNRTIs) due to its minimal interaction with rifampicin compared to Nevirapine.¹³ Furthermore, in this case, prophylactic treatment with cotrimoxazole was administered. Cotrimoxazole prophylaxis is recommended for HIV patients with CD4 counts <200 cells/mm³ in the absence of TB, while HIV patients diagnosed with TB can receive cotrimoxazole prophylaxis regardless of CD4 count.¹²

This study demonstrated that despite mesenteric TB and HIV being complex and often challenging conditions to treat, successful resolution could be achieved through appropriate anti-TB therapy and suitable ARV treatment. Furthermore, the clinical implications of this study underscored the importance of ongoing and comprehensive monitoring in managing patients with mesenteric TB and HIV. This emphasized that with proper care and vigilant monitoring, patients with these serious conditions could achieve successful recovery. Additionally, the study highlighted the importance of using appropriate ARV in patients co-infected with HIV and TB. The study indicated that the use of ARVs in combination with anti-TB therapy could contribute to improved recovery and effective clinical management. Moreover, the study also made a significant contribution to the medical literature by reporting rare cases and highlighting successful resolutions in managing patients with mesenteric TB and HIV co-infection. The information provided in this case report served as a valuable source of knowledge for healthcare practitioners in caring for similar patients. Thus, the study not only provided a better understanding of the management of mesenteric TB and HIV co-infection but also emphasized the importance of appropriate treatment, ongoing monitoring, and the role of ARV therapy in achieving successful recovery for patients with these conditions.

This study had several limitations. First, no laparoscopic evaluation was performed in this case report, which may have limited the comprehensive assessment of the patient's condition. Second, since the study reported only on a single case, the findings might not have been generalizable to a broader population. Different patients could have responded differently to treatment, and factors such as co-morbidities and individual variations could have affected outcomes. Additionally, the study might have had a limited follow-up period, which might not have captured long-term outcomes or potential relapses of mesenteric TB or HIV. Longer-term follow-up would have provided more robust evidence of the durability of treatment effects. These limitations should have been considered when interpreting the findings of the study.

CONCLUSION

The diagnosis of mesenteric TB and HIV co-infection requires a comprehensive approach involving clinical presentation assessment, physical examination, radiological imaging, and confirmation through anatomic pathology examination. Effective management of mesenteric TB and HIV co-infection necessitates the administration of appropriate treatment and comprehensive, ongoing monitoring. Overall, the study provides valuable insights into the management of this challenging clinical scenario and underscores the importance of evidence-based approaches in clinical practice for mesenteric TB and HIV. By emphasizing the importance of a thorough diagnostic process and tailored treatment strategies, the study contributes to improving patient outcomes and enhancing the quality of care for individuals with these co-infections.

ETHICS APPROVAL AND CONSENT TO PARTICIPATE

The patient has provided informed consent for the composition of this case report.

CONFLICTS OF INTEREST

We have no conflict of interest

FUNDING SOURCES

We have no source of funding

ACKNOWLEDGMENT

The authors would like to express their gratitude to the Director of RSUD Bangil Kabupaten Pasuruan and all medical committee members at RSUD Bangil Kabupaten Pasuruan for their assistance in preparing this case report.

AUTHOR CONTRIBUTION

Conceptualization: NM, RSW; Data Curation: NM, RSW, ARR, BS, AS, LM, FK; Formal Analysis: NM, RSW; Investigation: NM, RSW, ARR, BS, AS, LM, FK; Project Administration: RSW; Resources: NM, SW; Methodology: NM, RSW; Software: NM, RSW; Visualization: NM, RSW; Supervision: NM, RSW, ARR, BS, AS, LM, FK; Validation: NM, RSW, ARR, BS, AS, LM, FK; Writing – Original Draft Preparation: NM, RSW, ARR, BS, AS, LM, FK; Writing – Review & Editing: NM, RSW, ARR, BS, AS, LM, FK. All authors have critically reviewed and approved the final draft and are responsible for the content and similarity index of the manuscript.

REFERENCES

1. de Vries G, van de Berg S, van Dam A, et al. Collaborative tuberculosis/HIV activities in the European Region. *ERJ Open Res* 2021;7(1):00721-2020.doi: 10.1183/23120541.00721-2020. PMID: 33532469
2. Mahendradhata Y, Ahmad RA, Lefevre P, et al. Barriers for introducing HIV testing among tuberculosis patients in Jogjakarta, Indonesia: a qualitative study. *BMC Public Health* 2008;8(1):385.doi: 10.1186/1471-2458-8-385. PMID: 19014468
3. Pai M, Dewan PK, Swaminathan S. Transforming tuberculosis diagnosis. *Nat Microbiol* 2023;8(5):756-759.doi: 10.1038/s41564-023-01365-3. PMID: 37127703
4. Lee JY. Diagnosis and treatment of extrapulmonary tuberculosis. *Tuberc Respir Dis (Seoul)* 2015;78(2):47-55.doi: 10.4046/trd.2015.78.2.47. PMID: 25861336
5. Kommi S, Ajit N, Sricharan KB, et al. An uncommon presentation of extrapulmonary tuberculosis masquerading as ovarian malignancy in a young female. *Indian J Nucl Med* 2021;36(4):437-440.doi: 10.4103/ijnm.ijnm_28_21. PMID: 35125765
6. Mehmood A, Ehsan A, Mukhtar M, et al. Acute mesenteric tuberculous lymphadenitis: A comparative analysis of twenty-one cases. *Cureus* 2019;11(4):e4454.doi: 10.7759/cureus.4454. PMID: 31205840
7. Jha DK, Pathiyil MM, Sharma V. Evidence-based approach to diagnosis and management of abdominal tuberculosis. *Indian J Gastroenterol* 2023;42(1):17-31.doi: 10.1007/s12664-023-01343-x. PMID: 36899289
8. Rana S, Farooqui MR, Rana S, et al. The role of laboratory investigations in evaluating abdominal tuberculosis. *J Family Community Med* 2015;22(3):152-157.doi: 10.4103/2230-8229.163029. PMID: 26392795
9. Allen VB, Gurusamy KS, Takwoingi Y, et al. Diagnostic accuracy of laparoscopy following computed tomography (CT) scanning for assessing the resectability with curative intent in pancreatic and periampullary cancer. *Cochrane Database Syst Rev* 2016;7(7):CD009323.doi: 10.1002/14651858.CD009323.pub3. PMID: 27383694
10. Debi U, Ravisankar V, Prasad KK, et al. Abdominal tuberculosis of the gastrointestinal tract: revisited. *World J Gastroenterol* 2014;20(40):14831-14840.doi: 10.3748/wjg.v20.i40.14831. PMID: 25356043
11. KEMENKES-RI. Pedoman nasional pelayanan kedokteran tata laksana tuberkulosis. Jakarta: Kementerian Kesehatan Republik Indonesia; 2020.
12. Torpey K, Agyei-Nkansah A, Ogyiri L, et al. Management of TB/HIV co-infection: the state of the evidence. *Ghana Med J* 2020;54(3):186-196.doi: 10.4314/gmj.v54i3.10. PMID: 33883764
13. Maemun S, Mariana N, Rusli A, et al. Early initiation of arv therapy among tb-hiv patients in indonesia prolongs survival rates! *J Epidemiol Glob Health* 2020;10(2):164-167.doi: 10.2991/jegh.k.200102.002. PMID: 32538033